

CLINICAL PATHWAY FOR MRI IN BACK PAIN IN ADULTS > 18 yrs

Name of patient D.O.B.

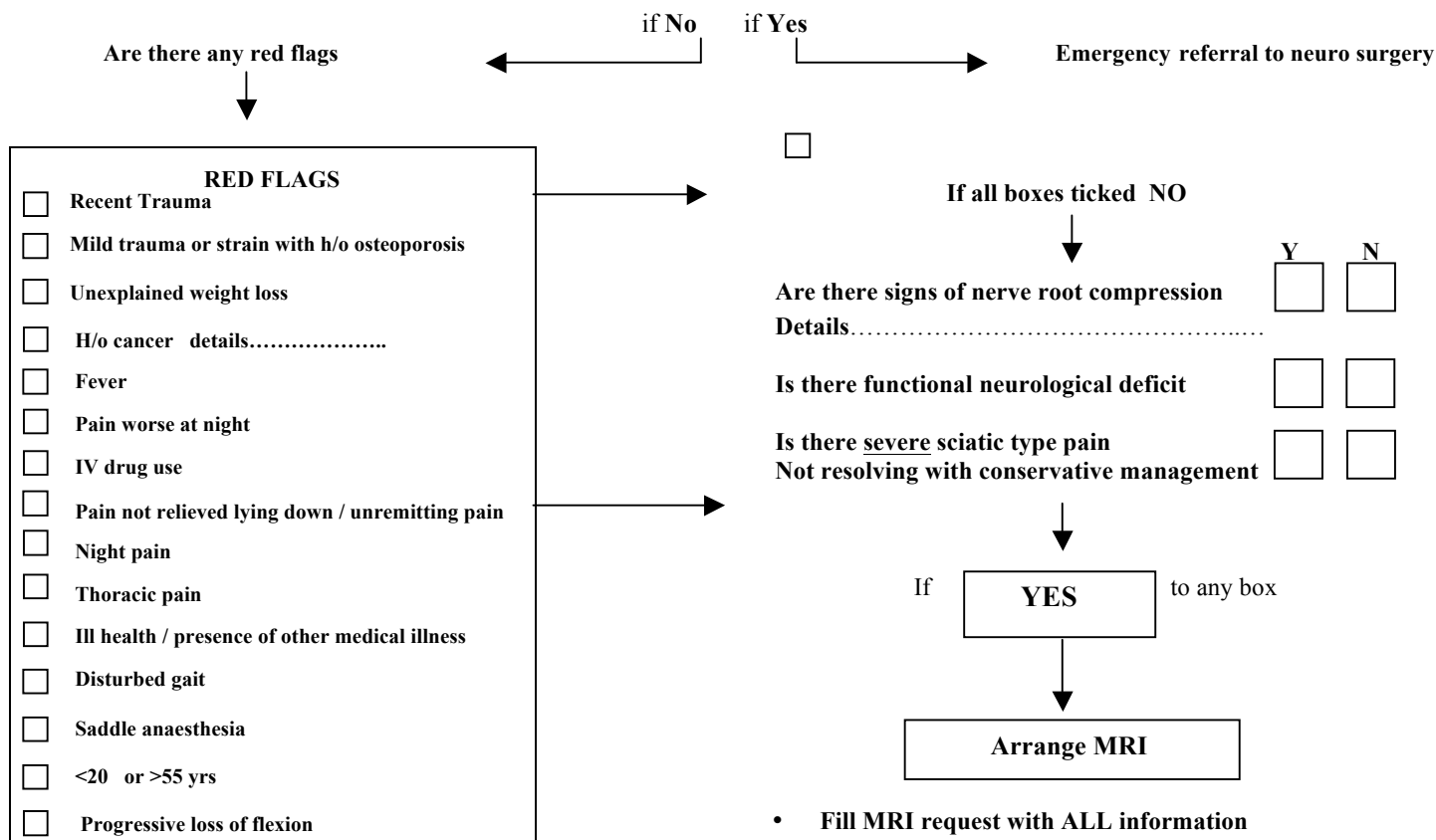
AddressGP referral

Date of request.....

• PTS PRESENT WITH ACUTE PRESENTATION OF LOW BACK PAIN TICK BOXES Y or N

Are there any signs of cord /cauda equine compression?

- Bladder/bowel dysfunction.
- Progressive neurological deficit in both legs



- Fill MRI request with ALL information
- Clinico – radiological correlation is ESSENTIAL as disc herniation occurs in the asymptomatic population

▪ No red flags → MRI NOT INDICATED IN ACUTE SETTING

▪ No compressive neuropathy

Arrange conservative management

If pain NOT settling after physio / conservative Mx Six Weeks

X-Ray can be helpful if ? osteoporotic collapse in elderly or suspected spondyloarthropathy in young patient

Consider MUST assessment

- ALL MRI's WILL BE BOOKED AND REPORTED WITHIN TWO WEEKS (approximately)
- THE MRI REQUEST/REPORT CAN BE DISCUSSED WITH THE DUTY RADIOLOGIST ON 3885 OR 2419

PLEASE FAX THIS REQUEST AND MRI SAFETY FORM TO: 020 8934 3291